

EKG Fundamentals

29yM with no PMHx brought in by EMS after syncopal episode at a music festival. He notes moderate alcohol and cocaine use. EKG was repeated on ED arrival.

HR: 97	BP: 135/85
RR: 20	O2 Sat: 98%

What is your interpretation of the first ECG?

History/Clinical Picture

T Waves

Rate

U Waves

Rhythm

PR Interval

Axis

QRS Width

P Waves

ST Segment

Q/R/S Waves

QT Interval

What is your interpretation of the repeat ECG?

History/Clinical Picture

T Waves

Rate

U Waves

Rhythm

PR Interval

Axis

QRS Width

P Waves

ST Segment

Q/R/S Waves

QT Interval

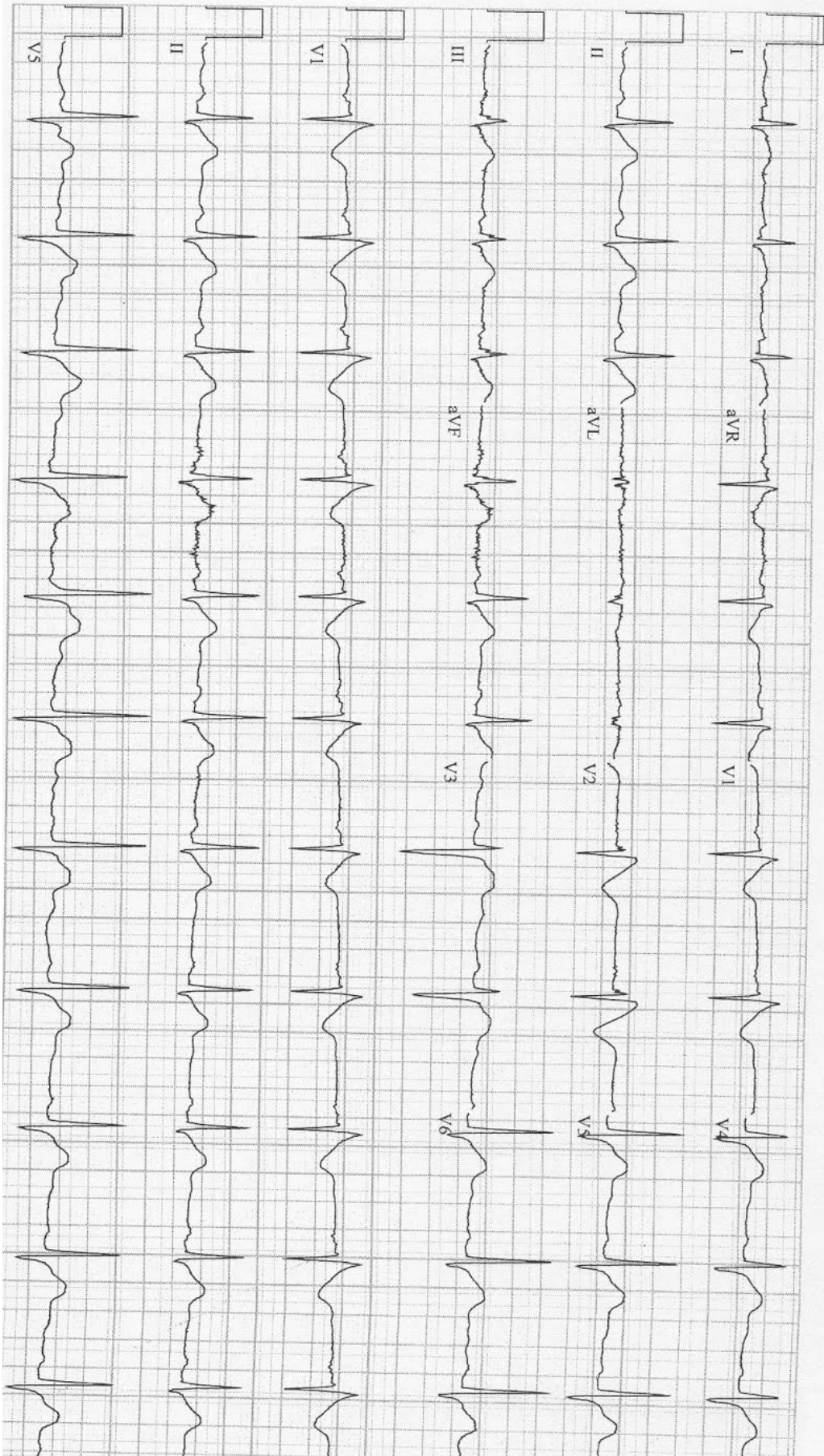
Are these EKGs suggestive or diagnostic? Is additional history is required?

Resource Links:

[Life in the Fast Lane](#) — great overview

[Dr. Steve Smith's Blog](#) — interesting case

EMS EKG



Triage EKG

