

# EM EKG Fundamentals

57yM with hx of HL, DM2 c/o palpitations and SOB for the past 72 hours. Sent to the ED from PMD's office for an abnormal EKG.

HR: 95	BP: 160/110
RR: 18	O2 Sat: 96%

## What is your interpretation of the EKG from the PMD's office?

History/Clinical Picture	T Waves
Rate	U Waves
Rhythm	PR Interval
Axis	QRS Width
P Waves	ST Segment
Q/R/S Waves	QT Interval

## What is your interpretation of the triage EKG?

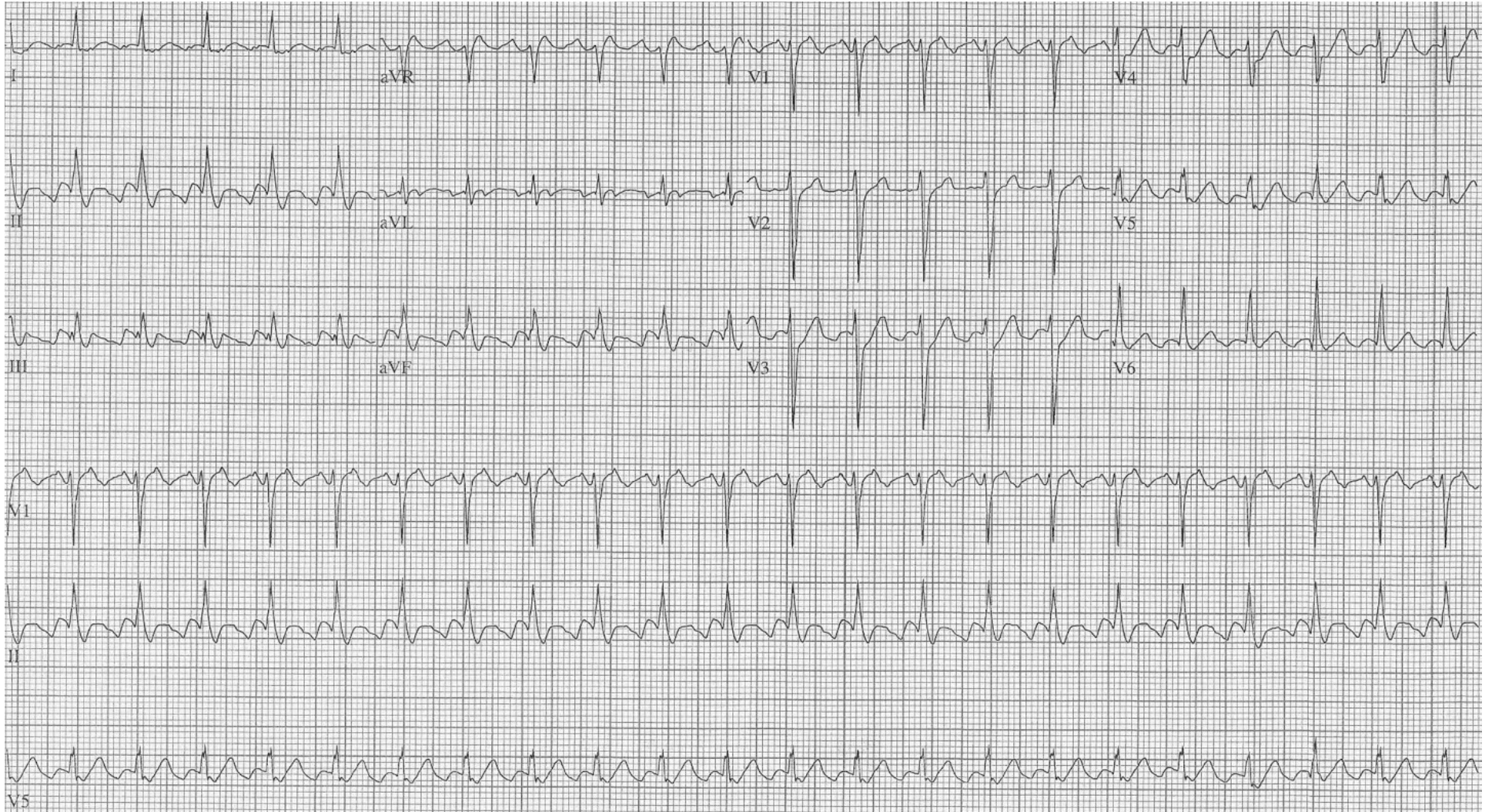
History/Clinical Picture	T Waves
Rate	U Waves
Rhythm	PR Interval
Axis	QRS Width
P Waves	ST Segment
Q/R/S Waves	QT Interval

Resource Links: [Life in the Fast Lane](#)

[Life in the Fast Lane](#)

[Dr. Steve Smith's Blog](#)

# Office EKG



# Triage EKG

