



Foundations EKG I - Unit 2, Case 6

65 y/o M with a history of a STEMI 3 weeks ago presents to the ED from his cardiologists office because an outpatient echo this morning showed a “clot in my heart”. He has had not chest pain since his MI 3 weeks ago.

HR: 65 BP: 118/66

RR: 12 O2 Sat: 98%

What is your interpretation of the EKG?

History/Clinical Picture

Rate

Rhythm

Axis

P Waves

Q/R/S Waves

T Waves

U Waves

PR Interval

QRS Width

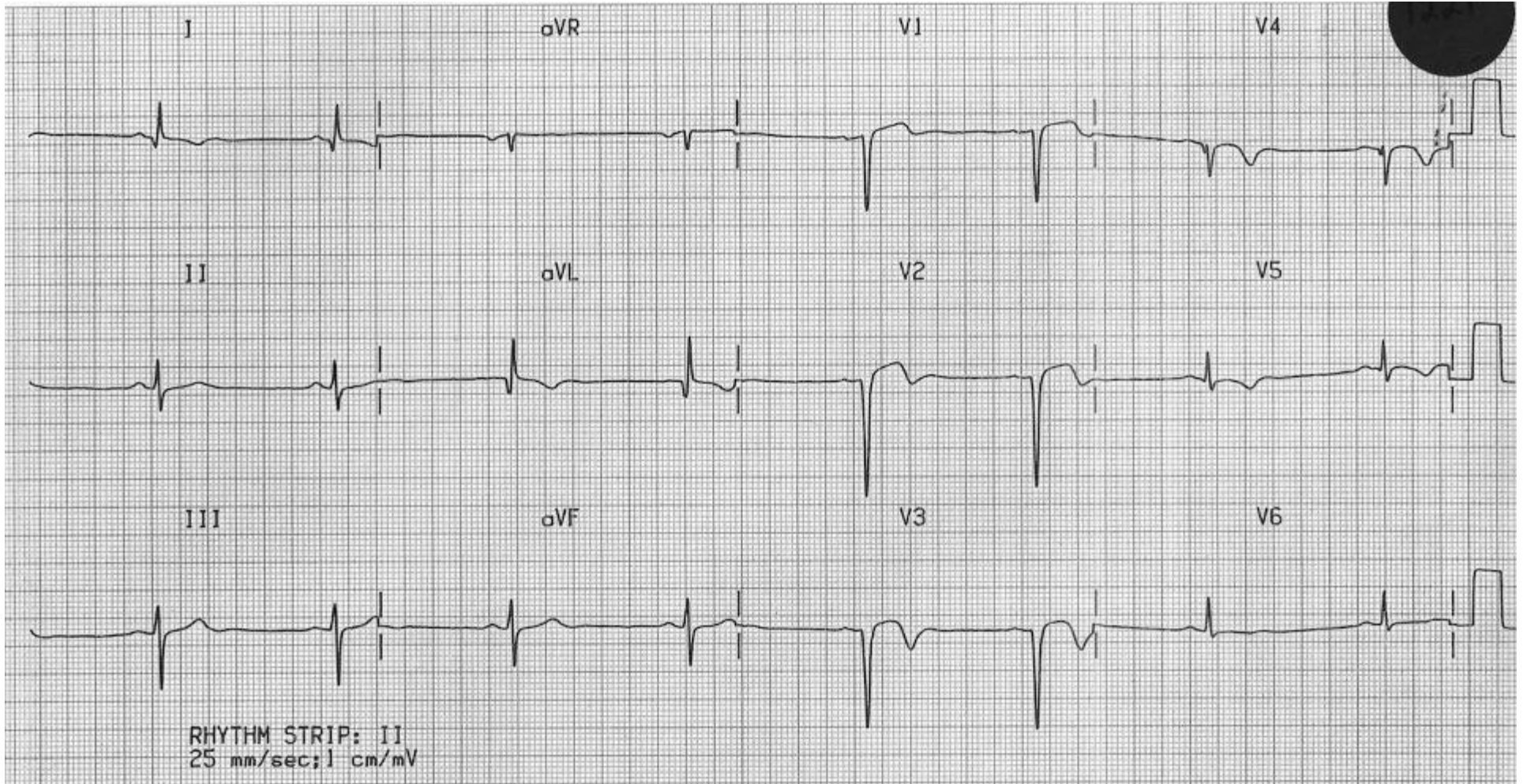
ST Segment

QT Interval

Putting the EKG together with the clinical history, what do you think is going on with this patient?

How should this patient be managed?

Triage EKG



Courtesy of Edward Burns of [Life in the Fast Lane](#)

[Creative Commons License](#)