

Foundations EKG I - Unit 3, Case 11



20yF with history of anxiety on Xanax complaining of intermittent palpitations. Denies CP, SOB. No acute distress. Carrying discharge paperwork from another ED that reveals a discharge diagnosis of anxiety.

| | |
|--------|-------------|
| HR: 96 | BP: 121/82 |
| RR: 14 | O2 Sat: 98% |

What is your interpretation of the EKG?

History/Clinical Picture

Rate

Rhythm

Axis

P Waves

Q/R/S Waves

T Waves

U Waves

PR Interval

QRS Width

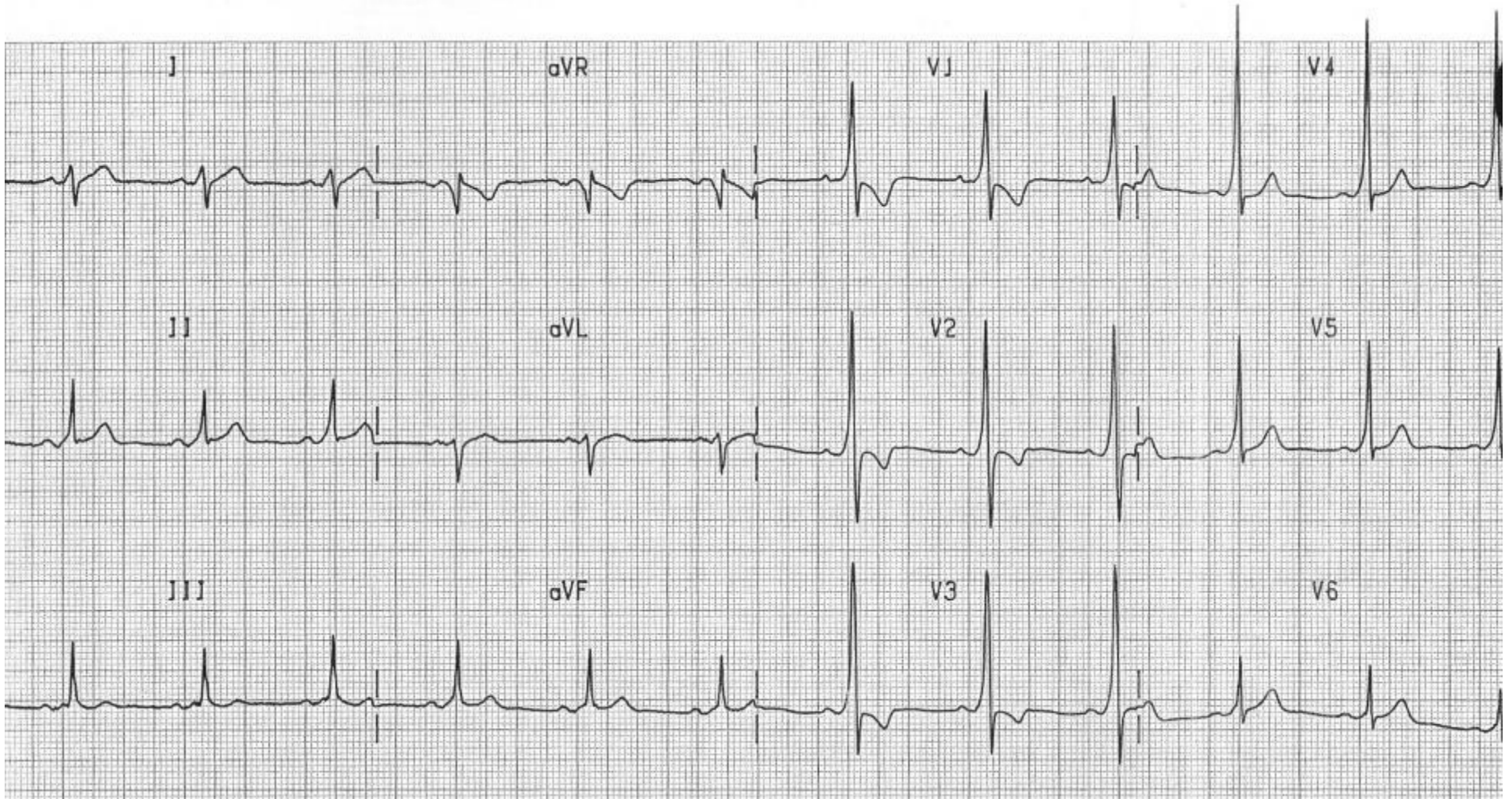
ST Segment

QT Interval

Considering the clinical history and the ECG, what do you think is going on with this patient?

What supraventricular tachycardia is particularly dangerous for this patient?

Triage EKG



Courtesy of Edward Burns of [Life in the Fast Lane](#)

[Creative Commons License](#)