

# Foundations EKG I - Unit 4, Case 16

*82 y/o F with a PMH of CAD and ischemic cardiomyopathy with an EF of 45% presents for syncope. She arrives pale and diaphoretic and reports feeling lightheaded.*

HR: 28

BP: 72/41

RR: 20

O2 Sat: 95%

## What is your interpretation of the EKG?

History/Clinical Picture

Rate

Rhythm

Axis

P Waves

Q/R/S Waves

T Waves

U Waves

PR Interval

QRS Width

ST Segment

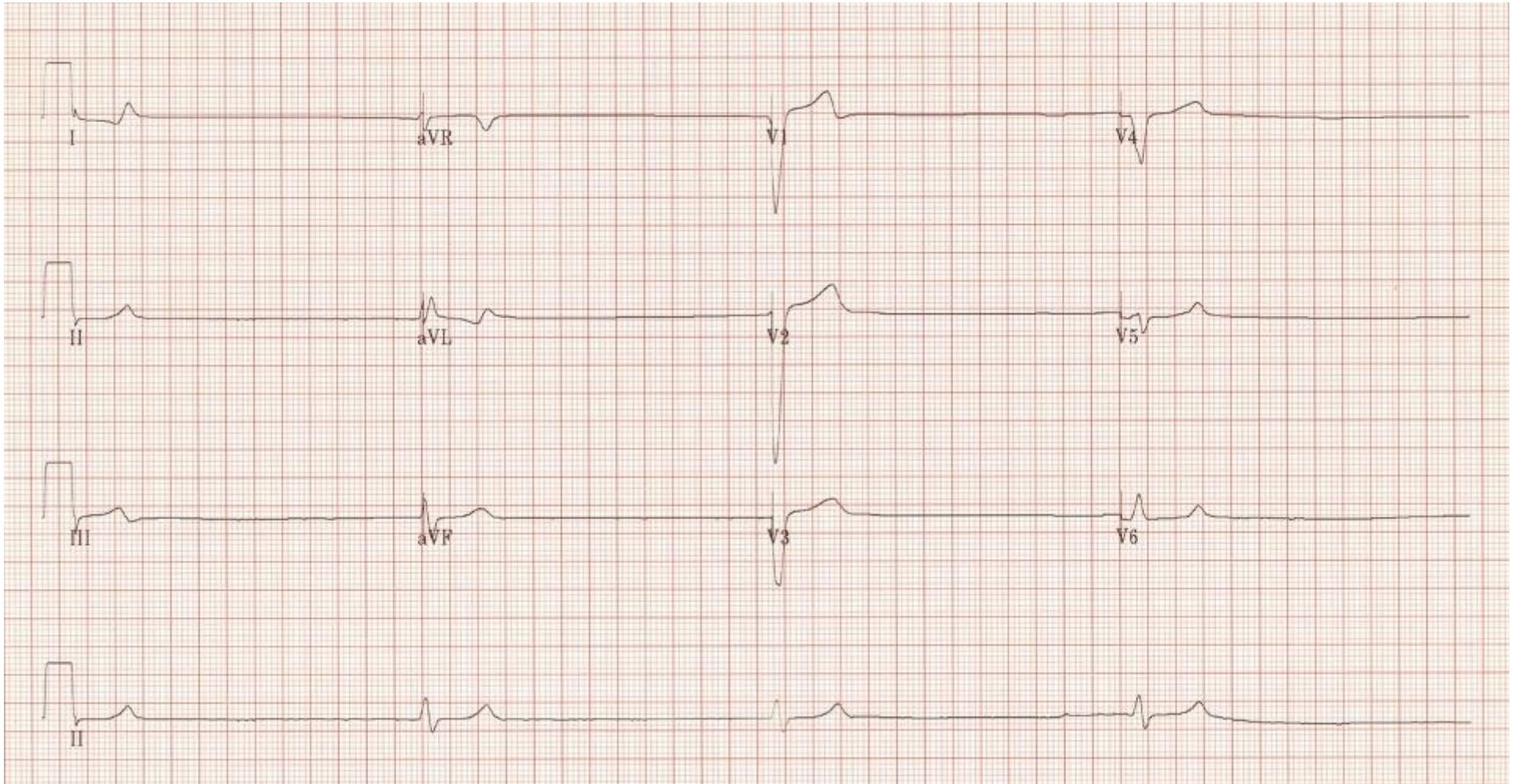
QT Interval

**What initial actions would you take in the ED?**

**What reversible precipitants of the patient's current condition would you want to evaluate for?**

**How would you disposition this patient?**

# Triage EKG



Courtesy of Edward Burns of [Life in the Fast Lane](#)

[Creative Commons License](#)