



# Foundations EKG II - Unit 8, Case 30

*64 y/o F with PMH HTN, HL, hypothyroidism who presents for crushing right shoulder pain and chest discomfort. She appears uncomfortable and reports the pain started 45 minutes ago.*

HR: 75      BP: 151/99

RR: 14      O2 Sat: 96%

## What is your interpretation of the EKG?

History/Clinical Picture

Rate

Rhythm

Axis

P Waves

Q/R/S Waves

T Waves

U Waves

PR Interval

QRS Width

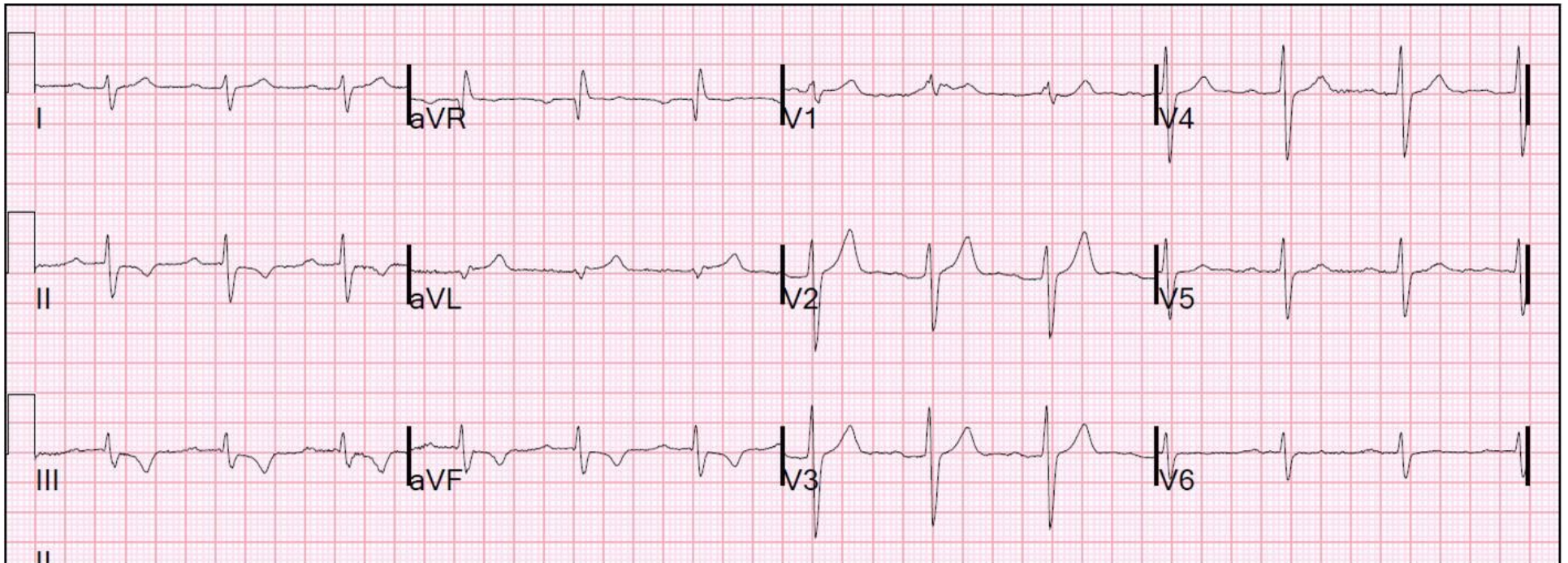
ST Segment

QT Interval

**Putting the EKG together with the clinical history, what do you think is going on with this patient?**

**How should this patient be managed?**

# Triage EKG



Courtesy of Edward Burns of [Life in the Fast Lane](#)

[Creative Commons License](#)