

Foundations EKG II - Unit 9, Case 33



37yF with ACL repair 3 weeks ago c/o SOB & CP. Hypoxic on room air. Repeat O2 sat of 96% on NRB.

HR: 102 BP: 100/60

RR: 28 O2 Sat: 88%

What is your interpretation of the EKG?

History/Clinical Picture

Rate

Rhythm

Axis

P Waves

Q/R/S Waves

T Waves

U Waves

PR Interval

QRS Width

ST Segment

QT Interval

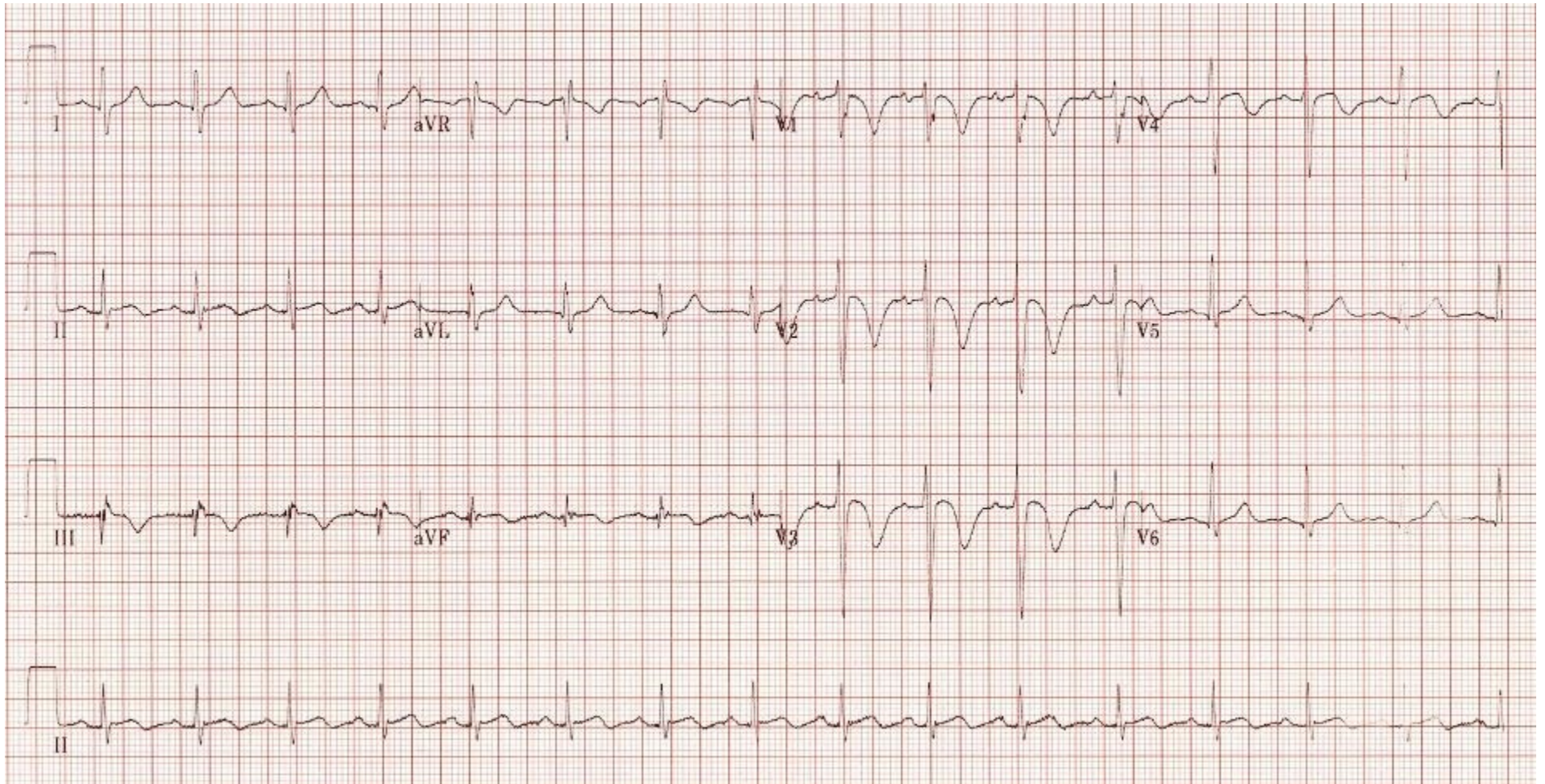
Putting the EKG together with the clinical history, what do you think is going on with this patient?

What diagnostic tests would you order?

How would you manage this patient in the ED?

What would you do if the patient were to arrest?

Triage EKG



Courtesy of Edward Burns of [Life in the Fast Lane](#)

[Creative Commons License](#)