

# Foundations EKG II - Unit 9, Case 35



*45 y/o M with PMH of obesity, HTN, DM, HL presents by EMS for 45 minutes of crushing substernal chest pressure and diaphoresis. By ED arrival the pain has completely resolved.*

HR: 65    BP: 164/102

RR: 12    O2 Sat: 97%

## **What is your interpretation of the EKG?**

History/Clinical Picture

Rate

Rhythm

Axis

P Waves

Q/R/S Waves

T Waves

U Waves

PR Interval

QRS Width

ST Segment

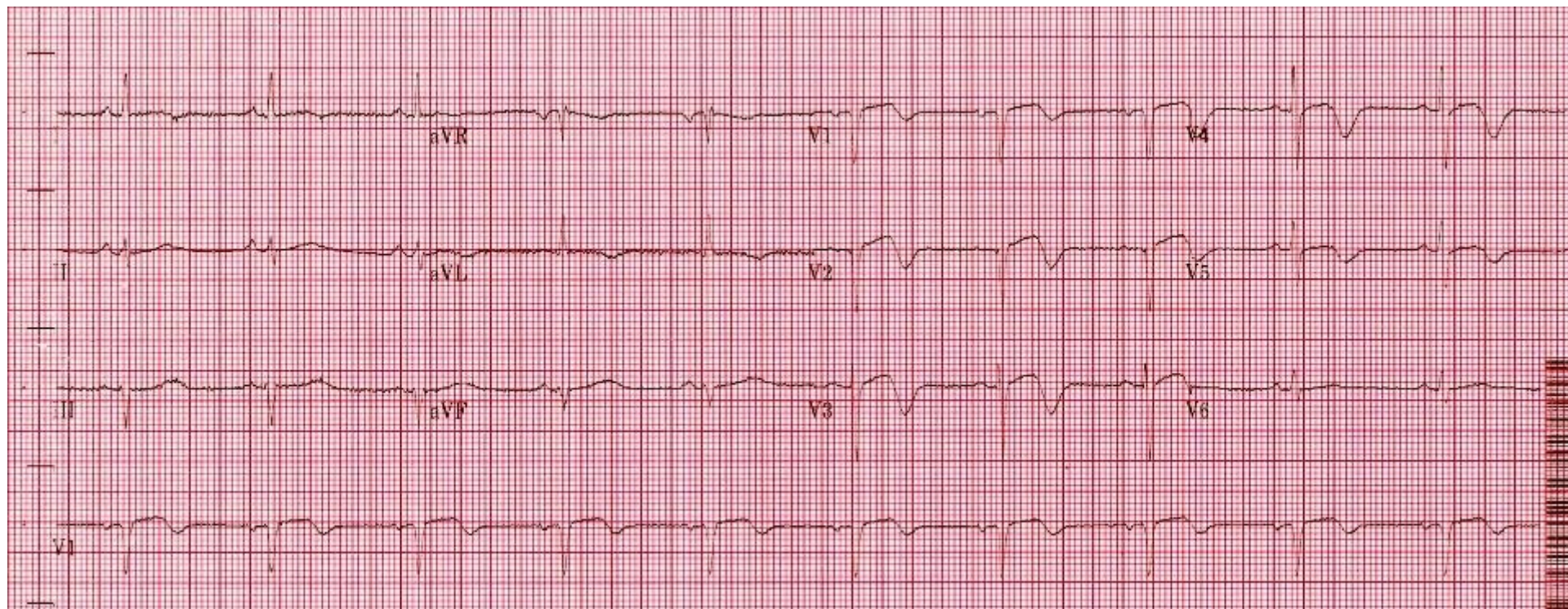
QT Interval

**What is the appropriate ED management of this patient?**

**Do you need to activate the cath lab?**

**How should this patient be dispositioned? Can he go home if he rules out for MI and remains chest pain free? If you decide to admit him, to what level of care should he be admitted?**

# Triage EKG



Courtesy of Edward Burns of [Life in the Fast Lane](#)

[Creative Commons License](#)