

Foundations EKG II - Unit 10, Case 37

73 y/o M with PMH of heart failure with reduced EF (HFrEF) presents to the ED with lightheadedness in the setting of 24 hours of vomiting and diarrhea.

HR: 70 BP: 100/70

RR: 16 O2 Sat: 97%

What is your interpretation of the EKG?

History/Clinical Picture

Rate

Rhythm

Axis

P Waves

Q/R/S Waves

T Waves

U Waves

PR Interval

QRS Width

ST Segment

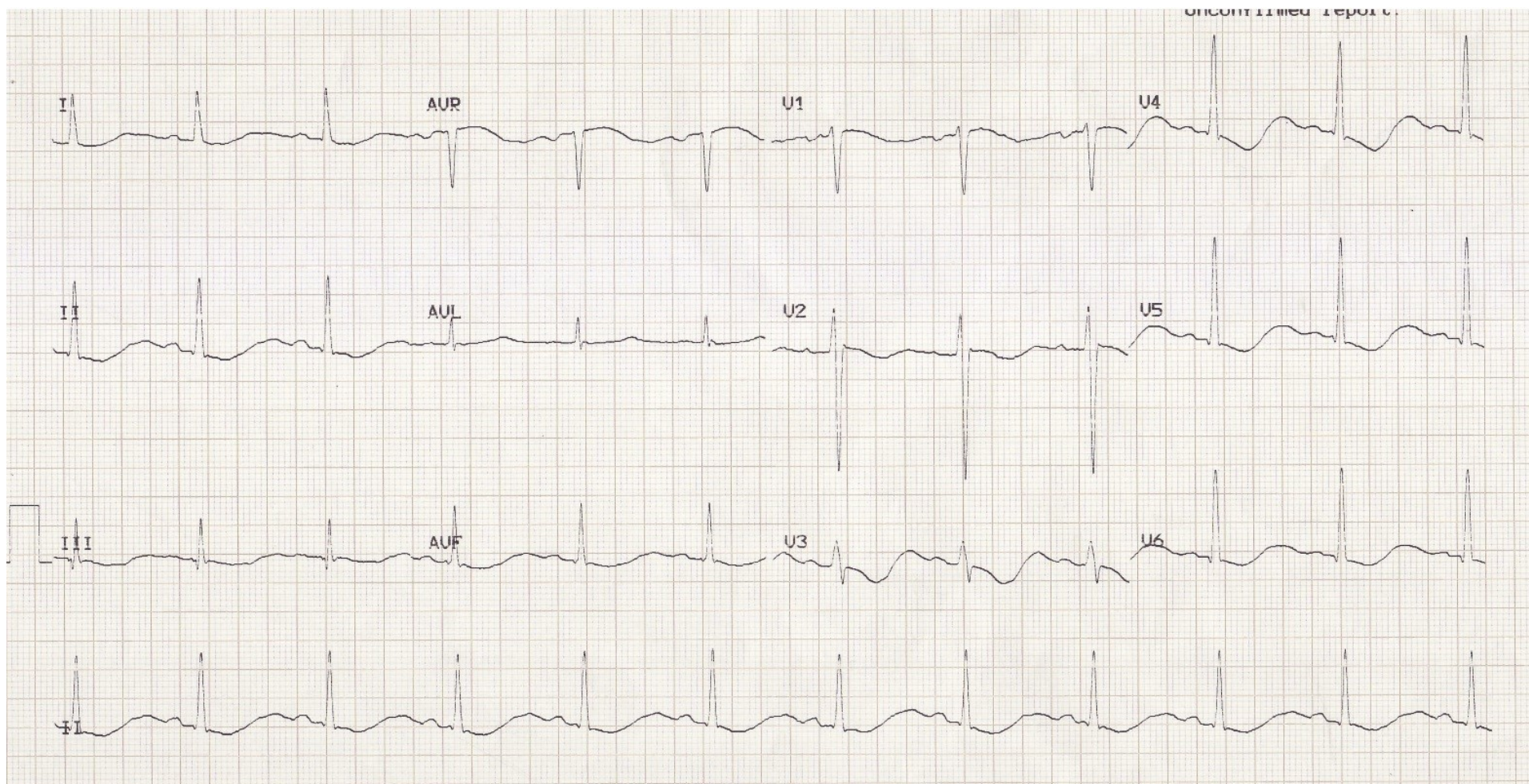
QT Interval

Putting the EKG together with the clinical history, what do you think is going on with this patient?

What lab values are important to check?

How should this patient be managed?

Triage EKG



Courtesy of Edward Burns of [Life in the Fast Lane](#)

[Creative Commons License](#)