

Foundations EKG II - Unit 11, Case 41

A 15yoM with a PMH of a “heart problem” presents for palpitations and lightheadedness. Review of his previous EKG reveals a narrow QRS with a shortened PR-interval.

HR: 260	BP: 110/70
RR: 20	O2 Sat: 99%

What is your interpretation of the EKG?

History/Clinical Picture

Rate

Rhythm

Axis

P Waves

Q/R/S Waves

T Waves

U Waves

PR Interval

QRS Width

ST Segment

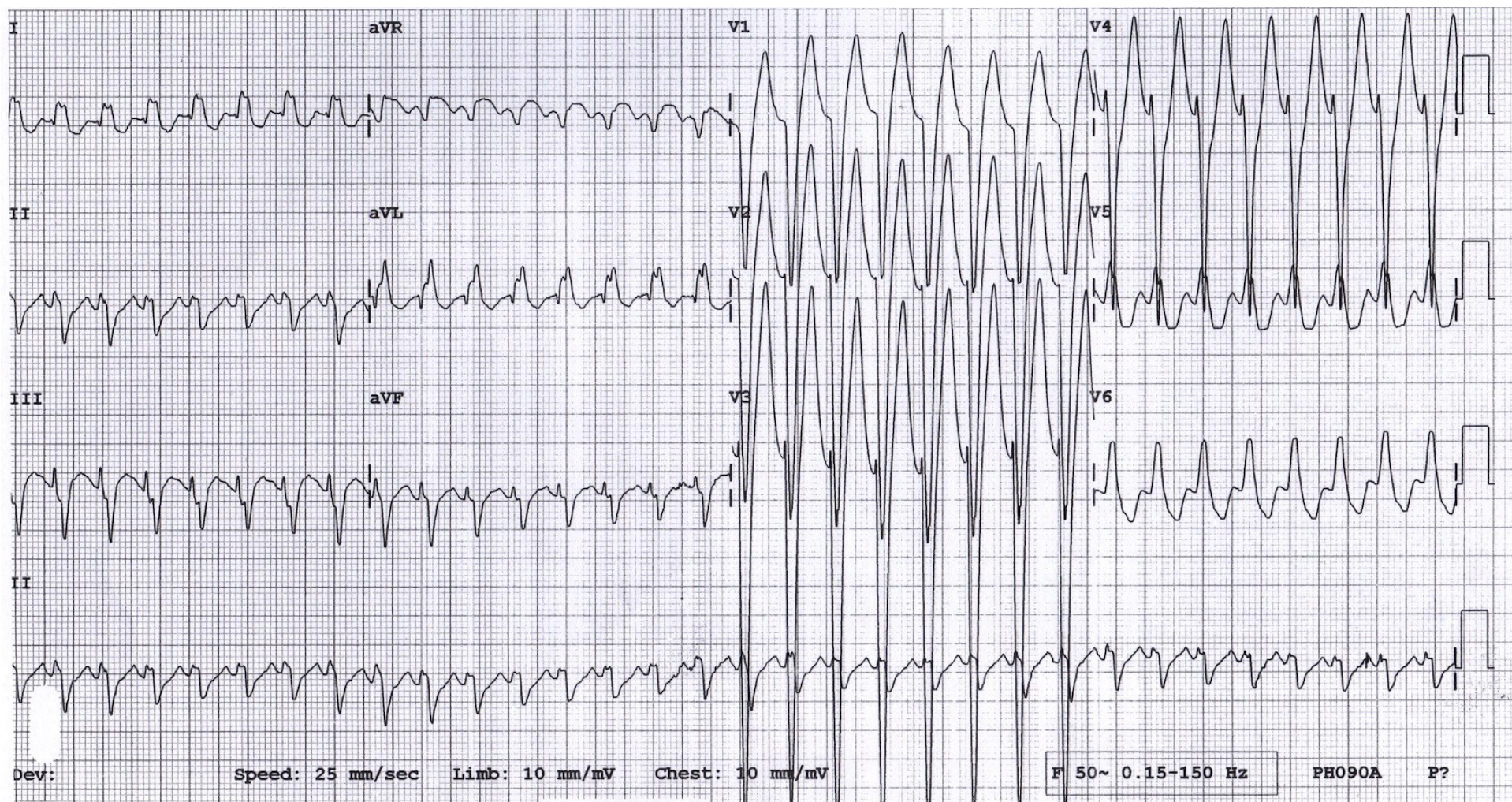
QT Interval

What is your differential diagnosis for the heart rhythm?

If in doubt, what rhythm should you assume?

What are your management options?

Triage EKG



Courtesy of Edward Burns of [Life in the Fast Lane](#)

[Creative Commons License](#)