

# Foundations EKG II - Unit 11, Case 42

*21 y/o M with no PMH presents for syncope without a prodrome that occurred while riding his bike. He reports an episode of palpitations and pre-syncope 3 weeks ago.*

HR: 70      BP: 120/71

RR: 12      O2 Sat: 98%

## What is your interpretation of the EKG?

History/Clinical Picture

Rate

Rhythm

Axis

P Waves

Q/R/S Waves

T Waves

U Waves

PR Interval

QRS Width

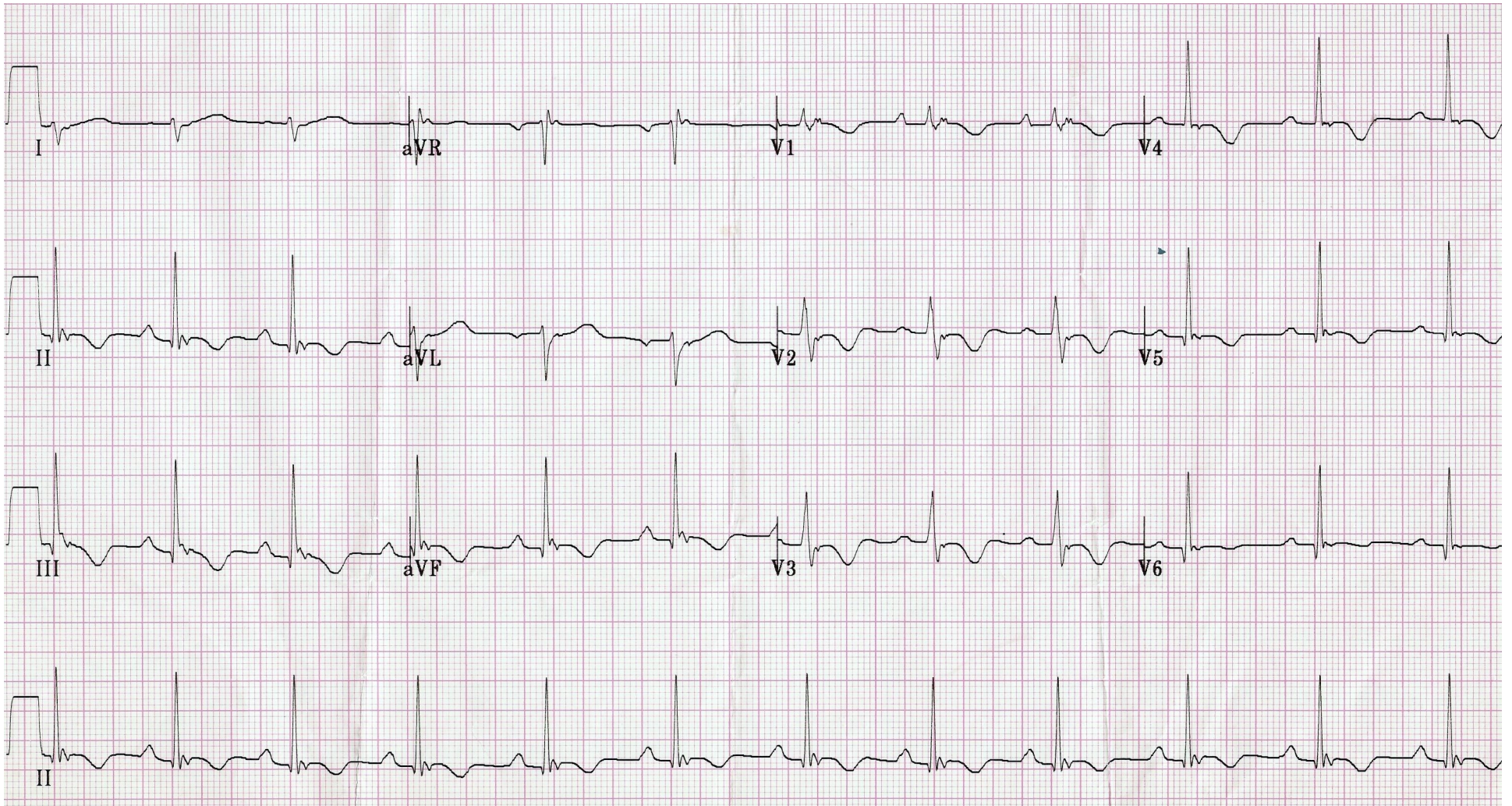
ST Segment

QT Interval

## What is your diagnosis?

**How would you disposition this patient? Does this episode of syncope merit inpatient admission, or is it safe to discharge him home?**

# Triage EKG



Courtesy of Edward Burns of [Life in the Fast Lane](#)

[Creative Commons License](#)