

Foundations EKG II - Unit 12, Case 45

77 y o F with PMH of severe aortic stenosis s/p transcatheter aortic valve replacement complicated by complete heart block now s/p pacemaker placement presents for pre-syncope.

HR: 65 BP: 130/81

RR: 14 O2 Sat: 98%

What is your interpretation of the EKG?

History/Clinical Picture

Rate

Rhythm

Axis

P Waves

Q/R/S Waves

T Waves

U Waves

PR Interval

QRS Width

ST Segment

QT Interval

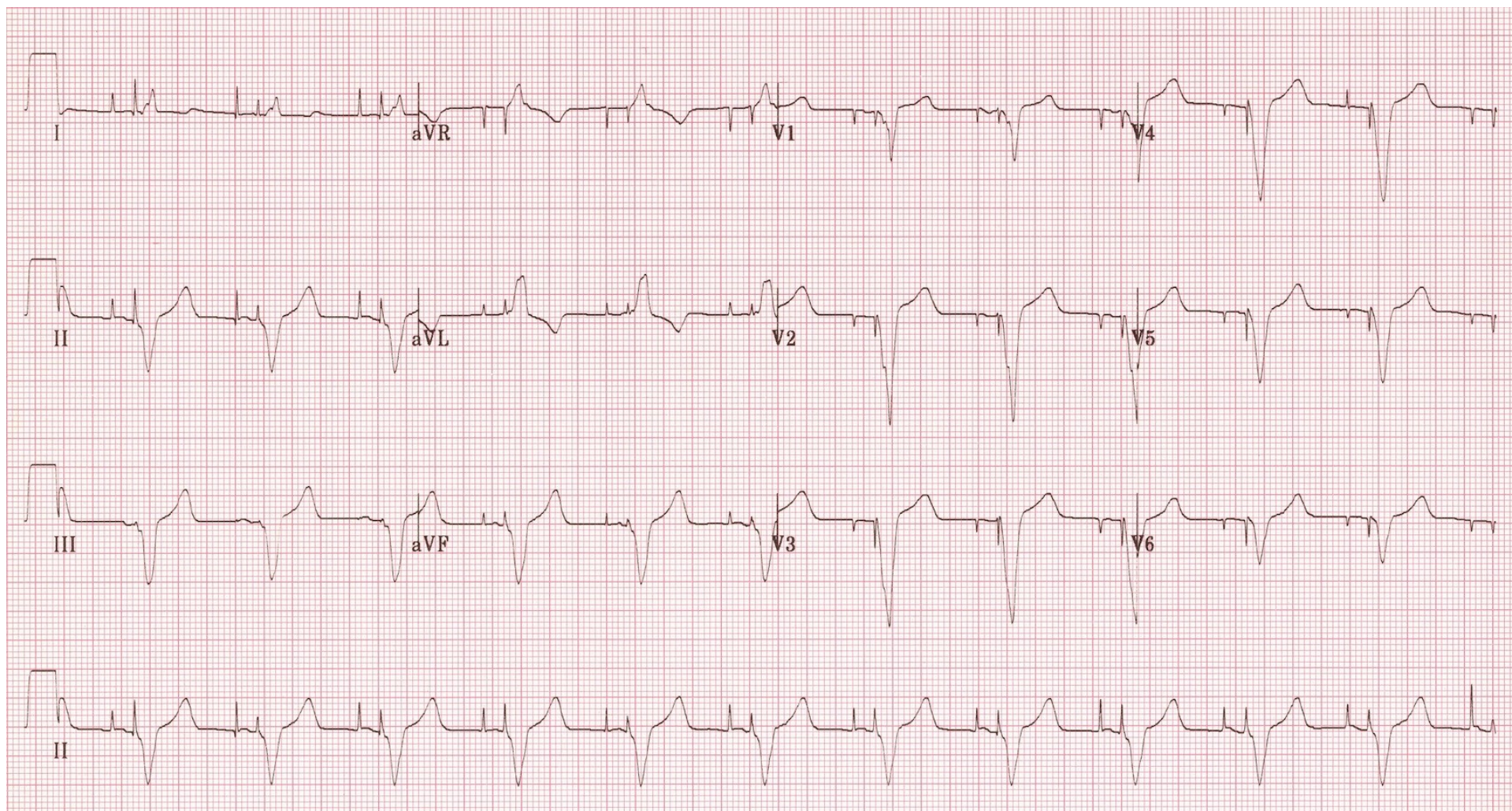
What is the rhythm?

Can you tell which chambers of the heart are being paced?

How are pacemakers programmed?

What does normal sensing and capture mean?

Triage EKG



EKG and later example courtesy of Edward Burns of [Life in the Fast Lane](#)

[Creative Commons License](#)