



Foundations Frameworks

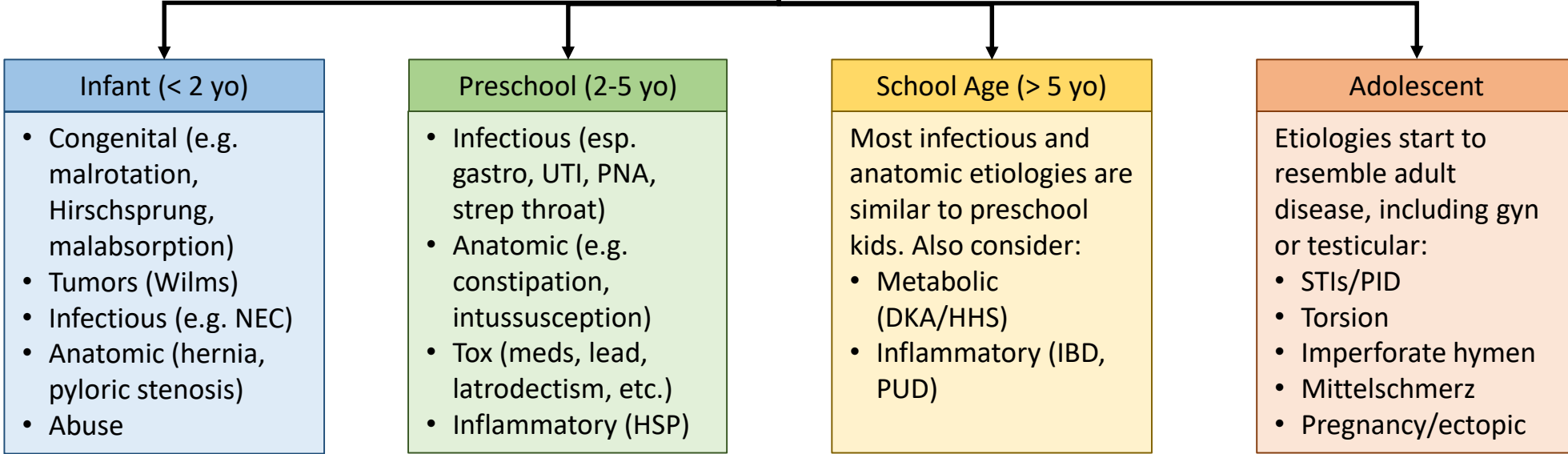
Approach to Pediatric Abdominal Pain

Author: Andrew Ketterer, MD, MA

Editors: Maneesha Agarwal, MD and Kristen Grabow Moore, MD, MEd

Thorough H&P
*Include history from parents/caregivers and child

Use similar cues to adult abdominal pain: inability to hold still suggests colicky pain, holding still suggests peritonitis. Young children may demonstrate inconsolability, which is a concerning finding. Remember that each age group has its own idiosyncratic concerns.



Imaging should be chosen based on level of concern. Minimizing radiation should be a goal of all pediatric imaging, meaning US and MR will often be the modalities of choice. Abdominal XR is common, but has low specificity and sensitivity for most etiologies of pain.