

Foundations EKG I - Unit 4, Case 16



82 y/o F with a PMH of CAD and ischemic cardiomyopathy with an EF of 45% presents for syncope. She arrives pale and diaphoretic and reports feeling lightheaded.

HR: 28 BP: 72/41

RR: 20 O2 Sat: 95%

What is your interpretation of the EKG?

History/Clinical Picture

Rate

Rhythm

Axis

P Waves

Q/R/S Waves

T Waves

U Waves

PR Interval

QRS Width

ST Segment

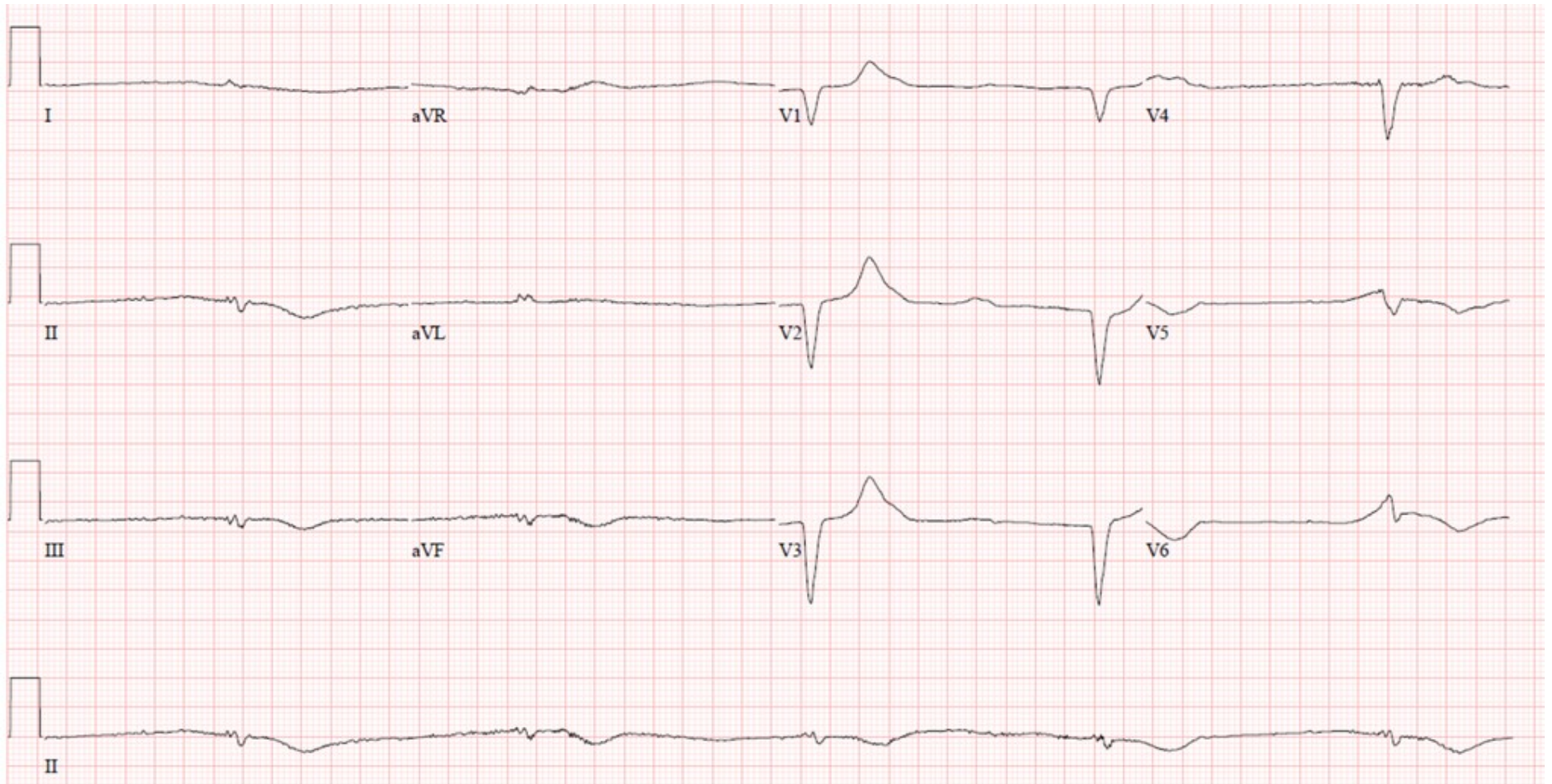
QT Interval

What initial actions would you take in the ED?

What reversible precipitants of the patient's current condition would you want to evaluate for?

How would you disposition this patient?

Triage EKG—Unit 4, Case 16



EKG courtesy of Shanna Jones, MD