

# Foundations EKG I - Unit 5, Case 20



*73yoF with a 50 pack year smoking history is admitted for shortness of breath and increased sputum production. She reports many prior hospitalizations for similar symptoms.*

HR: 115      BP: 120/70

RR: 22      O2 Sat: 90%

## What is your interpretation of the EKG?

History/Clinical Picture

Rate

Rhythm

Axis

P Waves

Q/R/S Waves

T Waves

U Waves

PR Interval

QRS Width

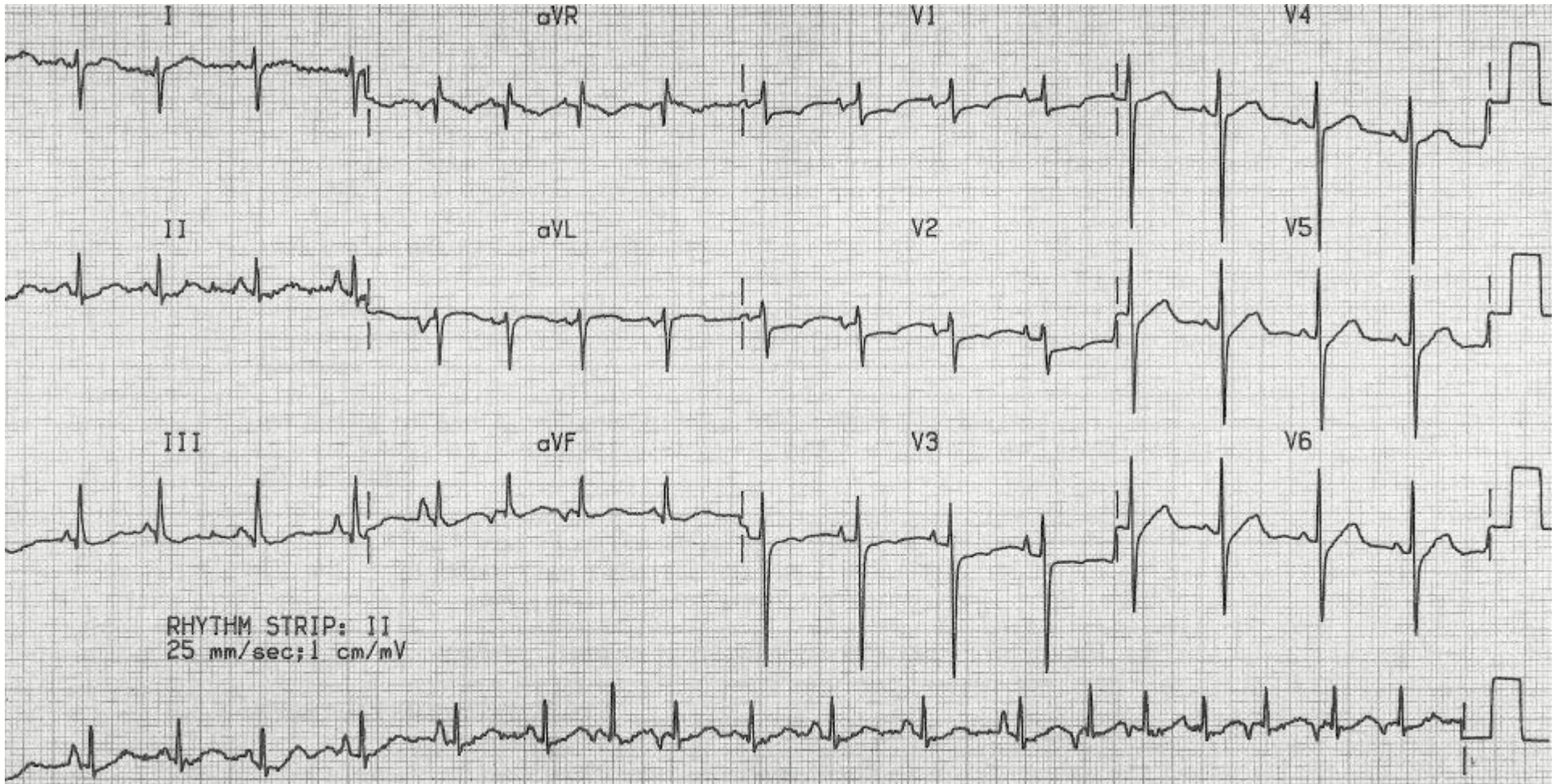
ST Segment

QT Interval

**What underlying conditions are associated with this rhythm?**

**What electrolyte abnormalities should be evaluated for and corrected in patients with this rhythm?**

# Triage EKG—Unit 5, Case 20



Courtesy of Edward Burns of [Life in the Fast Lane](#)

[Creative Commons License](#)