

Foundations EKG I - Unit 6, Case 22



33yoM with no PMH presents for palpitations and pre-syncope that started acutely 30 minutes ago.

HR: 140 BP: 100/50

RR: 20 O2 Sat: 97%

What is your interpretation of the EKG?

History/Clinical Picture

Rate

Rhythm

Axis

P Waves

Q/R/S Waves

T Waves

U Waves

PR Interval

QRS Width

ST Segment

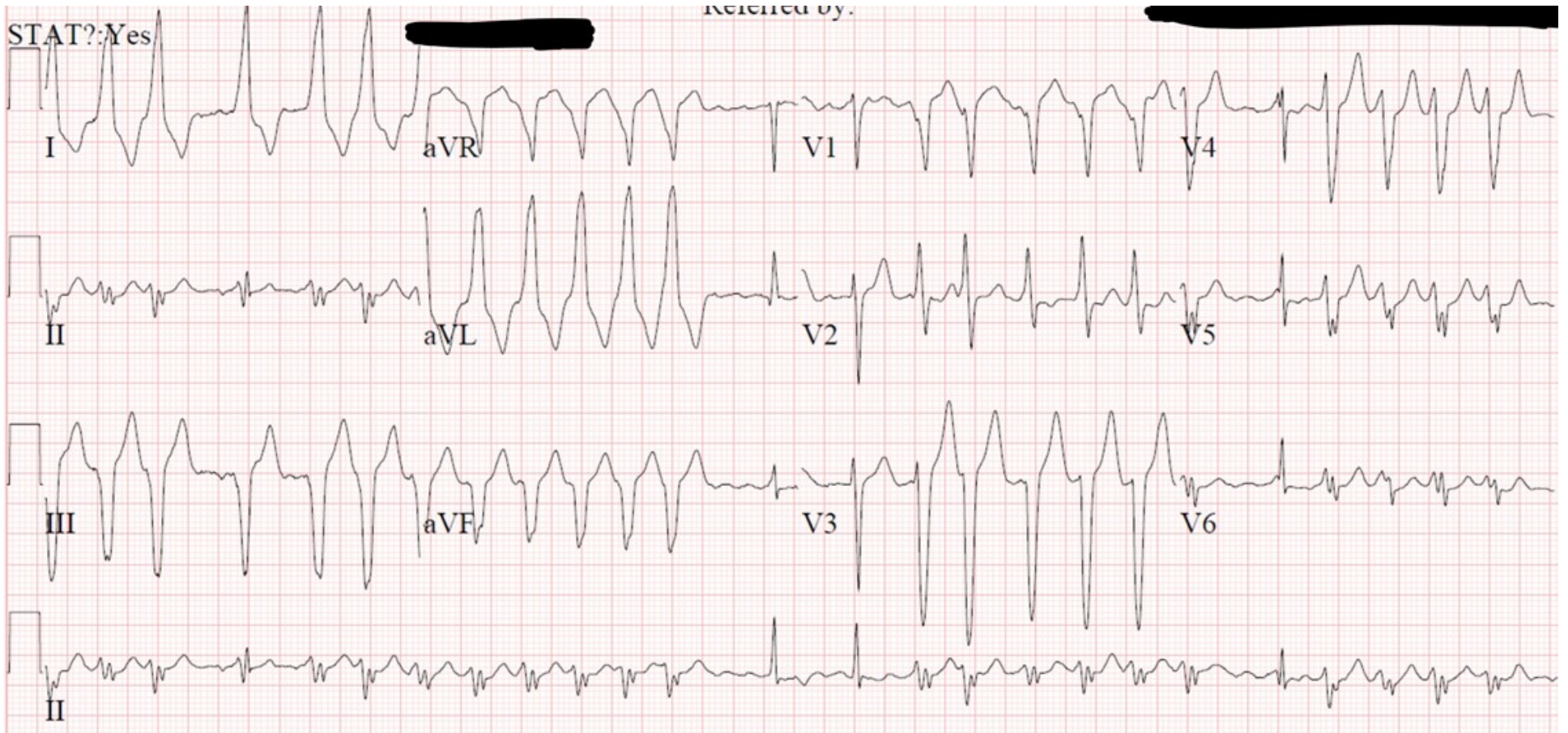
QT Interval

What underlying cardiac condition does this patient have?

What are your management options for this situation?

What medications are contraindicated in this situation?

Triage EKG—Unit 6, Case 22



EKG courtesy of Shanna Jones, MD