

Foundations EKG II - Unit 7, Case 26



54 y/o F with no PMH presents for syncope. She is currently asymptomatic.

HR: 100 BP: 119/64

RR: 12 O2 Sat: 99%

What is your interpretation of the EKG?

History/Clinical Picture

Rate

Rhythm

Axis

P Waves

Q/R/S Waves

T Waves

U Waves

PR Interval

QRS Width

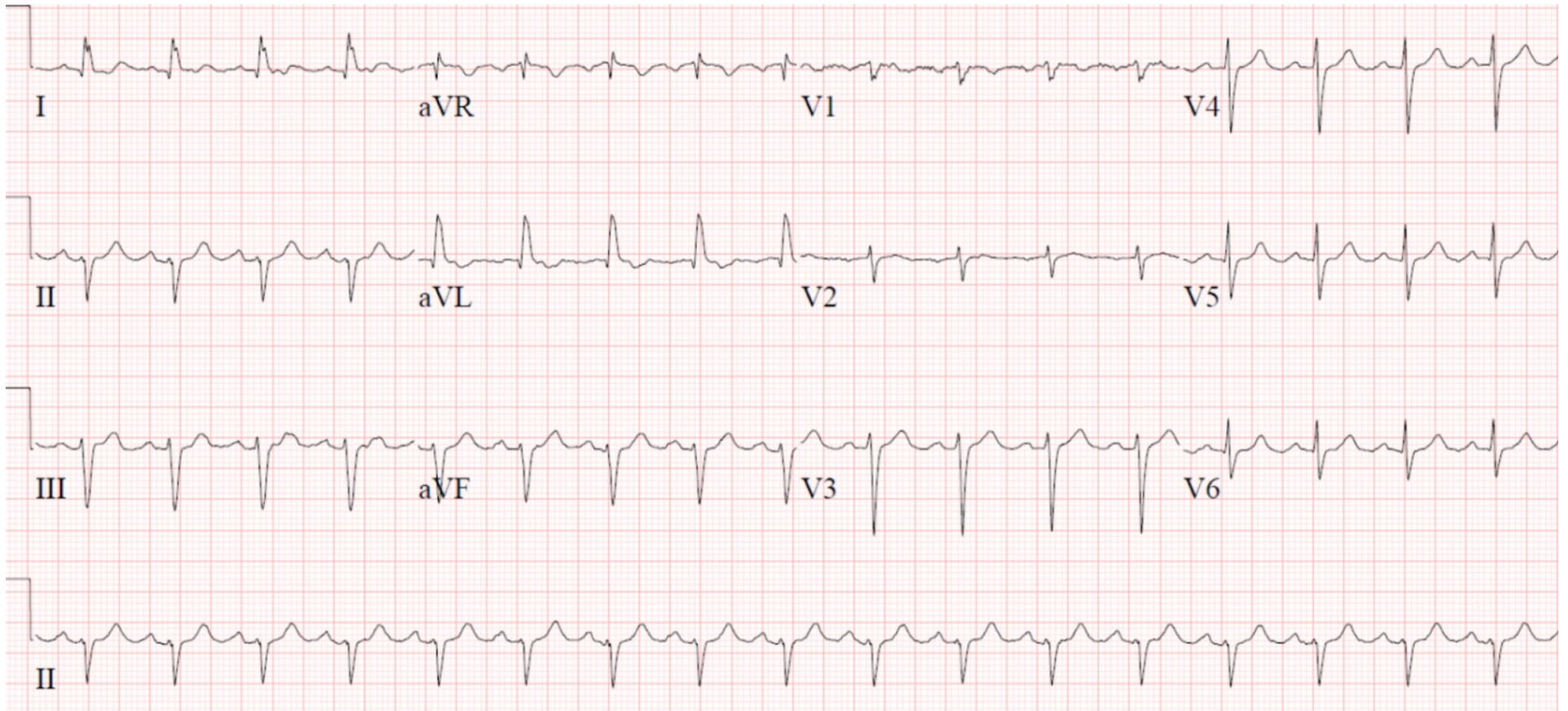
ST Segment

QT Interval

What part of the conduction system is affected in this EKG?

What is the clinical significance of this EKG finding?

Triage EKG—Unit 7, Case 26



EKG courtesy of Shanna Jones, MD