

Foundations EKG I - Unit 1, Case 3



53 y/o F with history of smoking and hyperlipidemia with chest pain for the past 2 hours.

HR: 95	BP: 130/110
RR: 18	O2 Sat: 96%

What is your interpretation of the EKG?

History/Clinical Picture

Rate

Rhythm

Axis

P Waves

Q/R/S Waves

T Waves

U Waves

PR Interval

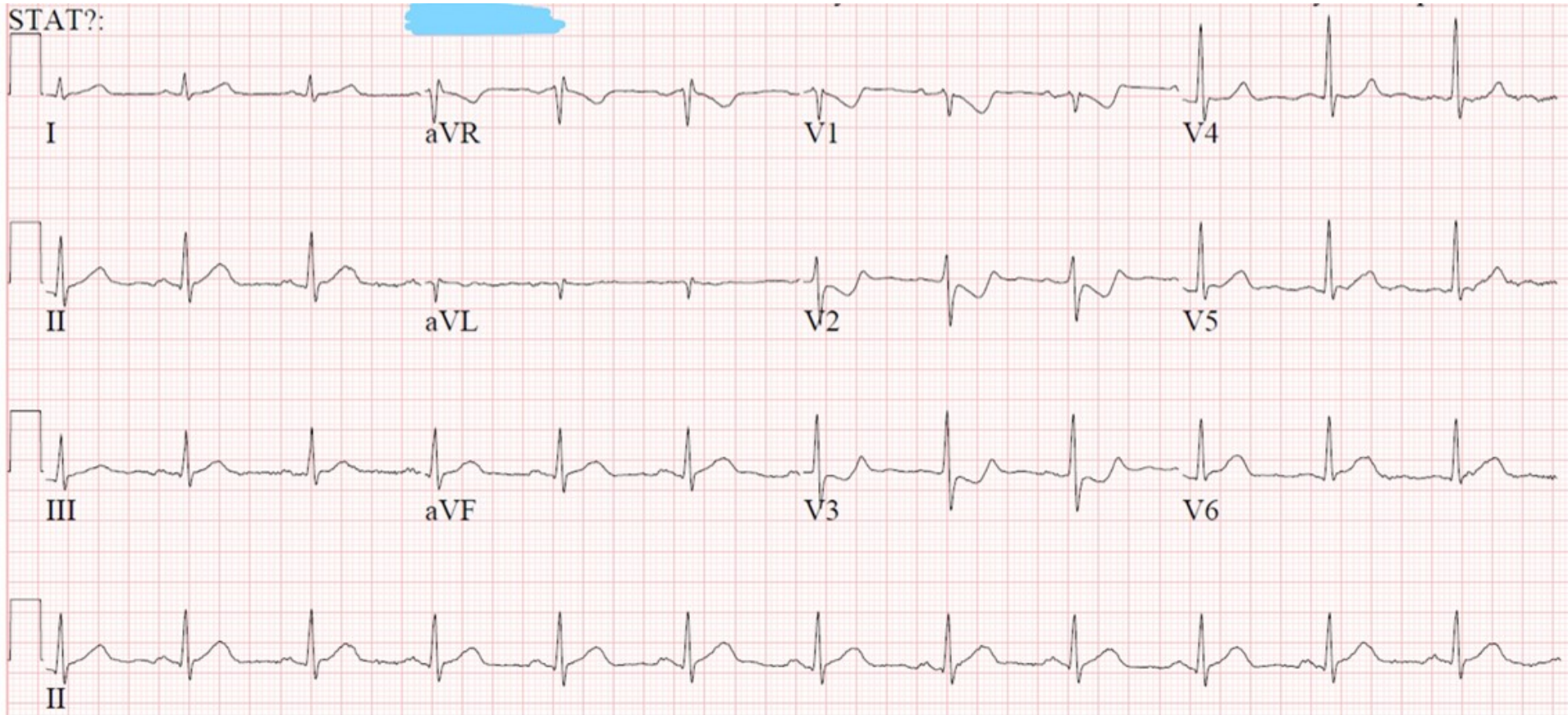
QRS Width

ST Segment

QT Interval

What changes on the standard EKG are suggestive of this diagnosis?

Triage EKG—Unit 1, Case 3



Repeat EKG—Unit 1, Case 3

