

Foundations EKG II - Unit 8, Case 30



64 y/o F with PMH HTN, HL, hypothyroidism who presents for crushing right shoulder pain and chest discomfort. She appears uncomfortable and reports the pain started 45 minutes ago.

HR: 100 BP: 150/100

RR: 14 O2 Sat: 96%

What is your interpretation of the EKG?

History/Clinical Picture

Rate

Rhythm

Axis

P Waves

Q/R/S Waves

T Waves

U Waves

PR Interval

QRS Width

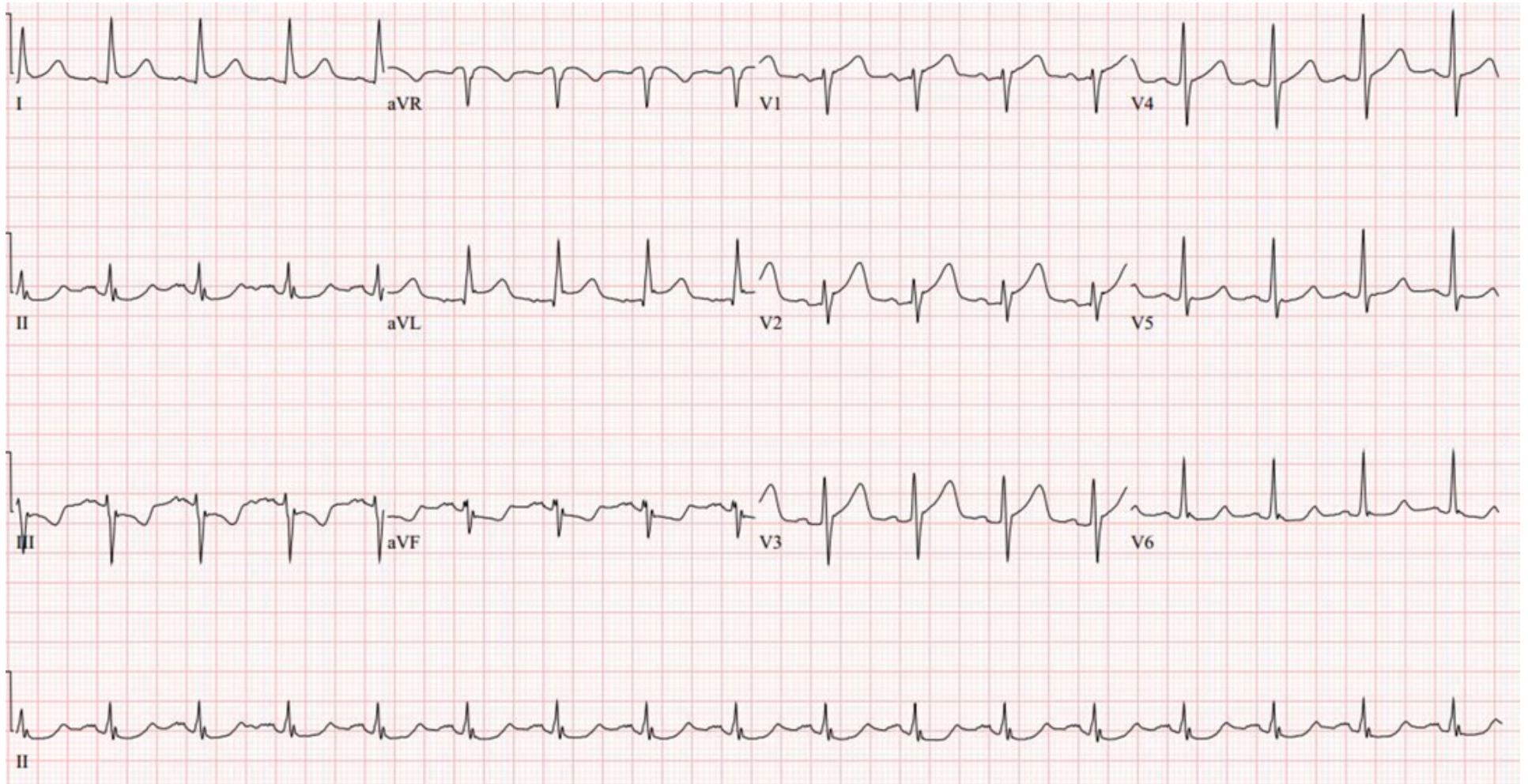
ST Segment

QT Interval

Putting the EKG together with the clinical history, what do you think is going on with this patient?

How should this patient be managed?

Triage EKG—Unit 8, Case 30



EKG courtesy of Shanna Jones, MD