

Foundations EKG II - Unit 12, Case 46



67 y/o F with PMH of atrial fibrillation complicated by tachy-brady syndrome s/p pacemaker placement presents with chest pain.

HR: 75 BP: 130/80

RR: 12 O2 Sat: 98%

What is your interpretation of the EKG?

History/Clinical Picture

Rate

Rhythm

Axis

P Waves

Q/R/S Waves

T Waves

U Waves

PR Interval

QRS Width

ST Segment

QT Interval

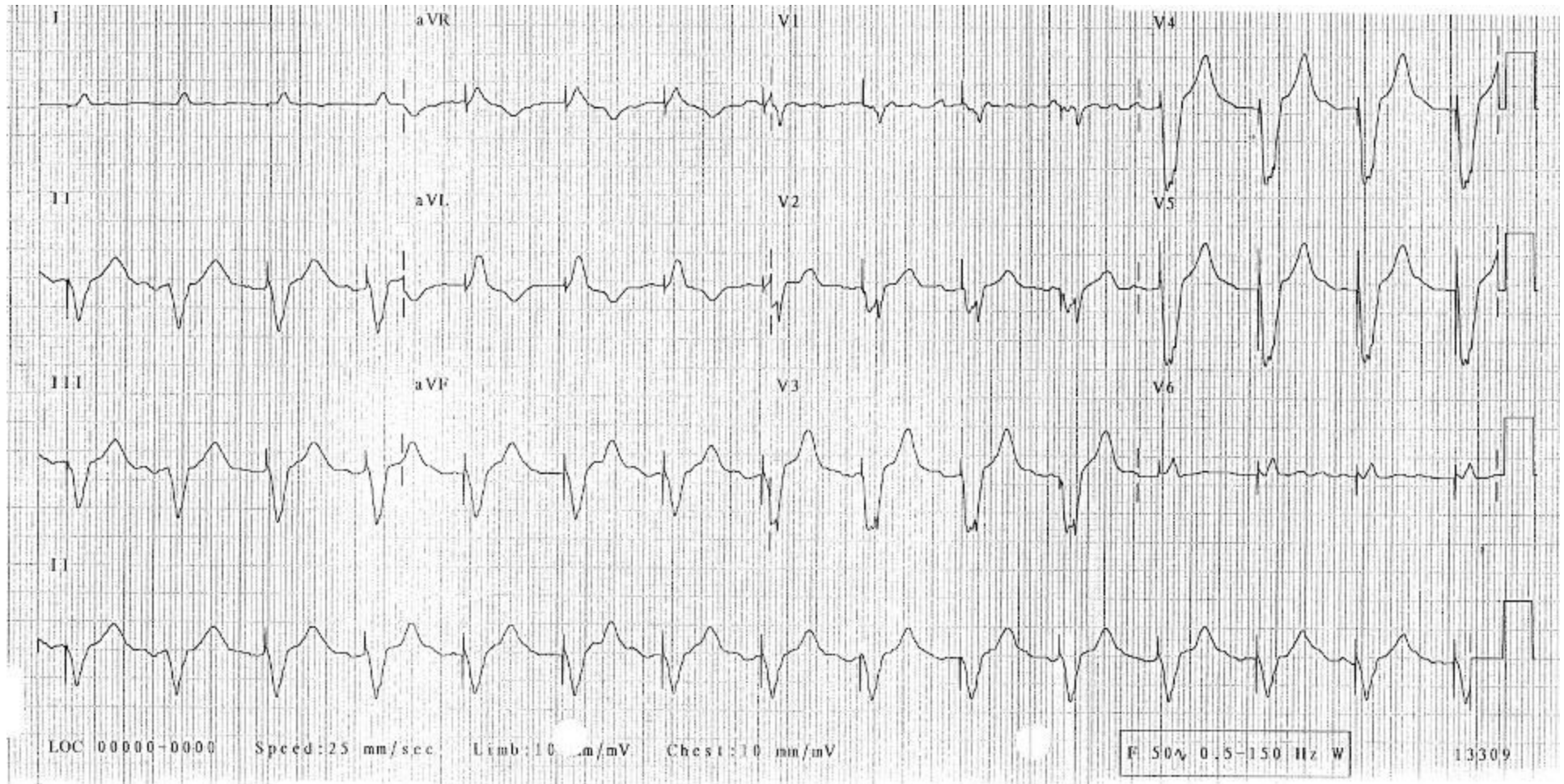
What is the rhythm?

Can you tell which chambers of the heart are being paced?

Are there any signs of pacemaker malfunction?

How would you disposition this patient?

Triage EKG—Unit 12, Case 46



Courtesy of Edward Burns of [Life in the Fast Lane](#)

[Creative Commons License](#)